



A Case of the Sphenoid Fungal Sinusitis Under Local Anesthesia

Kim JK^{1,2*} and Jung SJ³

¹Department of Otorhinolaryngology-Head and Neck Surgery, Eulji University College of Medicine, South Korea

²Department of Otorhinolaryngology-Head and Neck surgery, Seoul National University College of Medicine, South Korea

³Graduate School of International Studies, Yonsei University, South Korea

Abstract

Fungal sinusitis occurs as airborne fungi adhere to the mucous membranes of the nasal cavity and sinuses through respiratory inhalation. Fungal sinusitis manifests in various forms from simple irritation of nasal sinus mucosa to life-threatening diseases. Fungal sinusitis may be asymptomatic, the symptoms of fungal sinusitis include purulent rhinorrhea, facial pain and postnasal drip. Diagnosis of fungal sinusitis through nasal endoscopy is notably difficult. In computed tomography, fungal sinusitis is characterized by observations such as calcifications, heterogenous soft tissue density lesions, and periosteal thickening. The treatment is the endoscopic removal of fungal ball completely widening the sinus ostium. The sphenoid sinus, being the closest paranasal structure to the skull base, requires attention due to its adjacency to vital structures like the internal carotid artery and optic nerve. Preoperative imaging scrutiny and a meticulous surgical strategy should precede the treatment involving the sphenoid sinus. The authors present a successful case of the sphenoid fungal sinusitis patient of high-risk systemic disease with old age under local anesthesia.

Keywords: Fungal sinusitis; Nasal cavity; Sphenoid sinus; Preoperative imaging scrutiny

Introduction

Fungal sinusitis is one of the most common diseases of the paranasal sinuses. Fungal sinusitis occurs as airborne fungi adhere to the mucous membranes of the nasal cavity and sinuses through respiratory inhalation. Fungal sinusitis may be asymptomatic, the symptoms of fungal sinusitis include purulent rhinorrhea, facial pain and postnasal drip. Diagnosis of fungal sinusitis through nasal endoscopy is notable difficult. In computed tomography, fungal sinusitis is characterized by observations such as calcifications, heterogenous soft tissue density lesions, and periosteal thickening. The fungal sinusitis treatment is the endoscopic removal of Fungal Ball (FB) completely widening the sinus ostium. The sphenoid sinus is a developmental growth of the sphenoid bone in the posterosuperior segment of the sphenoid recess. Many important structures such as internal carotid artery are adjacent to the sphenoid sinus. So, preoperative imaging scrutiny and a meticulous surgical strategy should precede the treatment involving the sphenoid sinus to avoid fatal complication. The authors present a successful case of the sphenoid fungal sinusitis patient of high-risk systemic disease with old age under local anesthesia.

Case Presentation

The patient was 62 female, patient who visited the outpatient clinic complaining of headaches. The patient had an underlying systemic disease and was continuously received treatment for the underlying disease. Endoscopy and computed tomography showed a soft tissue density heterogenous lesion in the left sphenoid sinus (Figure 1). Accordingly, in consultation with the patient, endoscopic sinus surgery was planned under local anesthesia. The surgery was performed in a comfortable mood while maintaining sufficient communication with the patient, and the surgery was performed by one author (Figure 2A). Surgical position is as follows. A monitor screen is installed on the head of patient, the surgeon is located to the left of the patient. And the progression of the surgery is as follows. First, in order to process the surgery smoothly, gauzes contained epinephrine and lidocaine were sufficiently applied to the nasal cavity. Afterwards, the left nasal cavity was infiltrative-anesthetized using a syringe containing solution with 4% lidocaine and epinephrine diluted 1:100,000 (Figure 2B). Infiltrative anesthesia was done to the nasal septum, inferior turbinate,

OPEN ACCESS

*Correspondence:

Joon Kon Kim, Department of Otorhinolaryngology-Head and Neck Surgery, Eulji University College of Medicine, South Korea,

Received Date: 25 Apr 2024

Accepted Date: 15 May 2024

Published Date: 20 May 2024

Citation:

Kim JK, Jung SJ. A Case of the Sphenoid Fungal Sinusitis Under Local Anesthesia. *World J Surg Surgical Res.* 2024; 7: 1548.

Copyright © 2024 Kim JK. This is an open access article distributed under the Creative Commons Attribution License, which permits unrestricted use, distribution, and reproduction in any medium, provided the original work is properly cited.

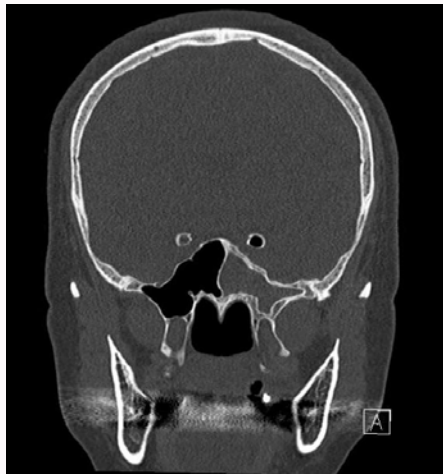


Figure 1: Preoperative evaluation. Using the Computed Tomography (CT) soft tissue density-heterogenous lesion of left sphenoid sinus was confirmed.

middle turbinate, superior turbinate, uncinate process mucosa and sphenoid sinus mucosa of left nasal cavity. During the repeated local anesthesia process, the author communicated with the patient to confirm that sufficient anesthesia had been achieved. Next, to secure a wide field of view, middle turbinate lateralization was performed during surgery. After identifying the sphenoid sinus ostium area using a seeker, opening the sphenoid sinus ostium using a curette was done. Then, the surgery is performed by expanding the removal area using an Endoscopic Debrider. As a result of the surgery, calcified FB and sinusitis were confirmed within the left sphenoid sinus using a 70-degree endoscope. No anatomical structure abnormalities or complications occurred during the surgery. The patient remained in stable condition until the end of the surgery. To prevent postoperative bleeding, appropriate electrocauterization was performed on the left sphenoid sinus surgery site, and non-absorbable packing material was used. After surgery, the author confirmed the postoperative condition at an outpatient clinic. Pathologic finding was confirmed, fungal sinusitis. Until postoperative 3 months later, the chief complaint symptom of the patient, headache was disappeared. Following up the postoperative lesion, the opening of left sphenoid sinus was good condition state, not closed and the mucosa of sinus was well healed state (Figure 3).

Discussion

The sphenoid sinus can be affected by a wide range of pathogens

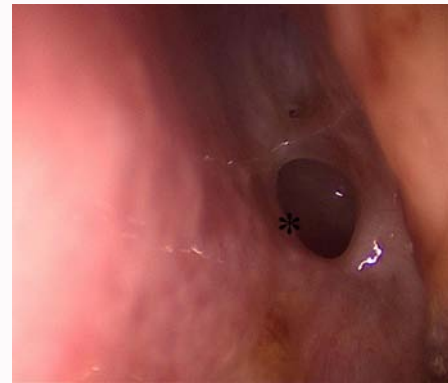

Figure 3: Postoperative follow-up 3 months image of the left sphenoid sinus lesions. The asterisk presents the opening of left sphenoid sinus.

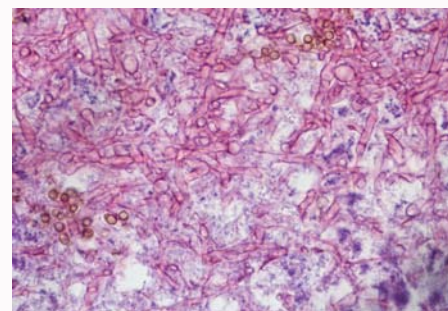


Figure 4: Histopathologic finding: Aspergillosis. Aspergillosis features the characteristic tangled and septated fungal hyphae, branched at 45 degrees.

due to its anatomical location. Usually, the sphenoid sinus occurs inflammatory disease; this contains fungal sinusitis including FB, bacterial sinusitis, mucocoeles and sinonasal polyps [1-4].

Pathological mechanism of FB in the paranasal sinus is still uncertain. According to recent papers, FB is formed by malfunction of the paranasal sinus ventilation. Sphenoid sinus FB is relatively rare, isolated FB only to sphenoid sinus and the FB spreading mechanism to the sphenoid sinus is not verified. It has been hypothesized that ostial closure creates an anaerobic environment favorable for growth of *Aspergillus*, or that chronic sinusitis predisposes to the development of FB. Environmental and hormonal factors may be involved in the pathogenesis of FBs [1,2,5-7]. Clinically, sphenoid sinus FB is generally found incidentally and characterized by

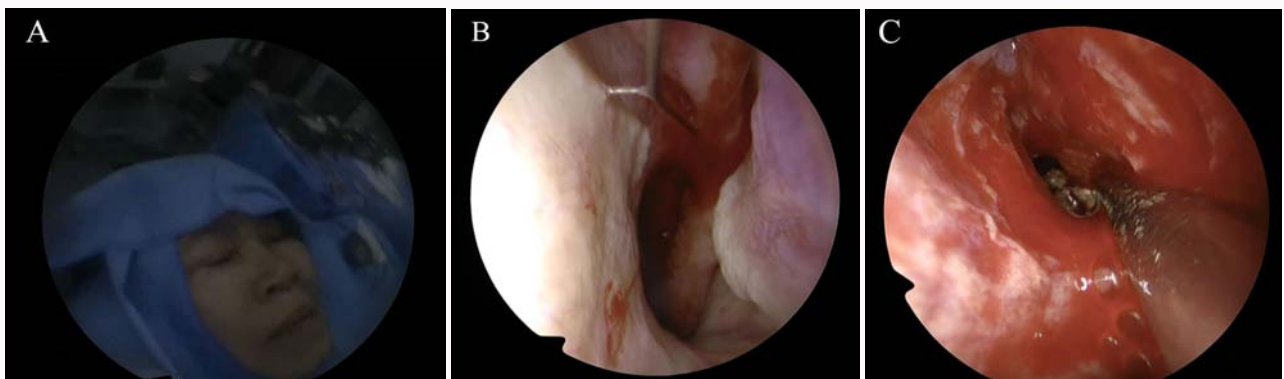


Figure 2: Intraoperative setting and endoscopic image. A) Preoperative operative field preparation for local anesthesia. B) Infiltrative local anesthesia to sphenopalatine artery area. C) The left sphenoid sinus opening procedure, Sphenoidotomy was done. The fungal material was confirmed.

nonspecific symptoms such as headache which is the most common symptom; it can be bilateral or more often unilateral (fronto-orbital, frontotemporal, retro-orbital, or occipital) [2,7-10]. Other common symptoms of sphenoid sinus FB are purulent anterior rhinorrhea, post-nasal drip, nocturnal cough, and nasal obstruction. Ocular disorders, such as diplopia and visual disturbance are not uncommon [9-12]. Two cases of preoperative ipsilateral blindness have been reported [9,12]. Most cases of visual impairment and eye muscle mobility recover after removal of the sphenoid sinus FB.

Preoperative nasal endoscopic examination can show secretions in the sphenoethmoidal recess, a congested surrounding mucosa which often impedes visualization of the sphenoid sinus ostium and bulging mucosa of sphenoid sinus. Usually, FB material is seen with mixture of chronic rhinosinusitis secretion, single FB identification of sphenoid sinus is rare.

CT scan is the definitive method of radiological diagnosis of sphenoid sinus disease. Sphenoid sinus FB shows as sphenoid sinus opacity which is usually heterogenous. Spontaneous hyper-densities often appear within the sinus opacity. Because of the content of the FB in iron, manganese, and calcium. A few cases may demonstrate radio-opaque ("metallic") densities within the sinus opacity which represent microcalcifications or dense hypha [1,2,11,13-15]. Common findings are bone thickening or sclerosis of sinus walls [6,7,15]. Foci of partial bone erosion of sphenoid sinus walls can occasionally be found on CT [7,13], even if the FB itself is not invasive.

MRI is considered to evaluate other differential diseases, such as fibro-osseous lesions, mucoceles, inflammation, encephaloceles/CSF leak, hemorrhage, and tumor. The FB presents an isointense-to decreased signal intensity on T1-weighted images and a much-decreased signal intensity on T2-weighted images (due to magnetic susceptibility of iron and manganese), sometimes surrounded by a T2-high-signal-intensity hyperplastic and inflammatory mucosa [2,11,16]. The FB does not enhance after gadolinium administration, comparing the surrounding inflammatory mucosa.

Final diagnosis of sphenoid sinus FB confirms by way of histopathological examinations. In the majority of cases, histopathology shows the characteristic tangled and septated fungal hyphae, which branch at 45°, characteristic of *Aspergillus* spp. [1,2,14,15,17,18] (Figure 4). Besides, histological examination is particularly useful in ruling out mucosal involvement by fungus [3,15]. The mucosa shows a nonspecific inflammation in which lymphocytes and plasma cells predominate [3].

The patient of this presentation study had at least one symptom, headache. Even if the FB is asymptomatic, surgical approach should be needed. Untreated sphenoid sinus FB can be the main focus of bacterial superinfection, such as meningitis, cavernous sinus thrombophlebitis and even brain empyema through bone erosion/defects of vascular routing.

The gold standard of sphenoid sinus FB treatment is surgery. The surgical approach removes fungal debris from the affected sinus and helps the disease lesion to reestablish its ventilation/drainage abilities. In the case of invasive fungal disease, anti-fungal medical treatment should be added. The surgical treatment is usually used by two approaches, trans-nasal approach and trans-ethmoidal approach. The trans-nasal approach has the merit to spare the ethmoid sinus mucosa. Trans-ethmoid approach is considered remaining adjacent combined posterior ethmoid sinus disease. In both approaches, Sphenoid sinus

FB requires a wide opening of the sphenoid sinus to achieve complete removal of fungal residues. Postoperative bone regeneration may be due to the reduced negative effect of inflammation on osteogenesis [19].

Performing surgical treatment of the sphenoid sinus, the operator should scrutinize the location of the structures surrounding the sinus due to major structures around the sphenoid sinus include the optic nerve and internal carotid artery. Because of damage to these structures can have fatal complications, so meticulous surgical procedure should be taken to avoid damaging them.

Recurrence of residual disease in the case of FB of the sphenoid sinus is much lower (0-3.6%) than FB of the maxillary sinus (0-22.5%) [2,6,7-9,11,13,16,19]. And complications of sphenoidotomy for FBs are nearly identical from those of sphenoid sinus surgery for any other disease [20,21]. The most common complication is epistaxis, mainly due to injury of the posterior nasal branch of the sphenopalatine artery. Bacterial superinfection can occur in the operated sphenoid sinus [7]. Rare complications are presented as the cerebrospinal fluid leak and injury to the optic nerve/carotid artery if the sphenoid sinus is dehiscent or much pneumatized superolaterally [20-24].

Conclusion

Sphenoid sinus FB is noninvasive disease related to fungal infection. If the disease is left as untreated state, it could lead to serious long-term complications. Preoperative nasal endoscopic examination and CT scan are the standard tools for diagnosis. MRI is used for complications and differential diagnosis. Endoscopic sphenoidotomy with removal of the fungus ball is the current treatment because it has proven effective and has a low morbidity and recurrence rate. Definitive diagnosis is postoperative histopathologic finding by means of mycologic and pathologic examinations. Surgical treatment of the sphenoid sinus could be successfully performed under local anesthesia if preoperative imaging scrutiny/meticulous surgical strategies precede the treatment involving the sphenoid sinus and the operator utilizes additional navigation systems when necessary.

References

- Klossek JM, Serrano E, Peloquin L, Percodani J, Fontanel JP, Pessey JJ. Functional endoscopic sinus surgery and 109 mycetomas of paranasal sinuses. *Laryngoscope*. 1997;107(1):112-7.
- Nicolai P, Lombardi D, Tomenzoli D, Villarcet AB, Piccioni M, Mensi M, et al. Fungus ball of the paranasal sinuses: Experience in 160 patients treated with endoscopic surgery. *Laryngoscope*. 2009;119(11):2275-9.
- Grosjean P, Weber R. Fungus balls of the paranasal sinuses: A review. *Eur Arch Otorhinolaryngol*. 2007;264(5):461-70.
- Lew D, Southwick FS, Montgomery WW, Weber AL, Baker AS. Sphenoid sinusitis: A review of 30 cases. *N Engl J Med*. 1983;309(19):1149-54.
- Hnatuk LA, Macdonald RE, Papsin BC. Isolated sphenoid sinusitis: The Toronto Hospital for sick children experience and review of the literature. *J Otolaryngol*. 1994;23(1):36-41.
- Chobilon MA, Jankowski R. What are the advantages of the endoscopic canine fossa approach in treating maxillary sinus aspergillomas. *Rhinology*. 2004;42(4):230-5.
- Leroux E, Valade D, Guichard JP, Herman P. Sphenoid fungus balls: Clinical presentation and long-term follow-up in 24 patients. *Cephalalgia*. 2009;29(11):1218-23.
- Socher JA, Cassano M, Filheiro CA, Cassano P, Felippu A. Diagnosis and treatment of isolated sphenoid sinus diseases: A review of 109 cases. *Acta*

- Otolaryngol. 2008;128(9):1004-10.
9. Castelnovo P, Pagella F, Semino L, De Bernardi F, Delu G. Endoscopic treatment of the isolated sphenoid sinus lesions. *Eur Arch Otorhinolaryngol.* 2005;262(2):142-7.
 10. Martin JT, Smith TL, Smith MM, Loehrl TA. Evaluation and surgical management of isolated sphenoid sinus disease. *Arch Otolaryngol Head Neck Surg.* 2002;128(12):1413-9.
 11. Pagella F, Pusateri A, Matti E, Giourgos G, Cavanna C, De Bernardi F, et al. Sphenoid sinus fungus ball: Our experience. *Am J Rhinol Allergy.* 2011;25(4):276-80.
 12. Lawson W, Reino AJ. Isolated sphenoid sinus disease: An analysis of 132 cases. *Laryngoscope.* 1997;107(12 Pt 1):1590-5.
 13. Dufour X, Kauffmann-Lacroix C, Ferrie JC, Goujon JM, Rodier MH, KarKas A, et al. Paranasal sinus fungus ball and surgery: A review of 175 cases. *Rhinology.* 2005;43(1):34-49.
 14. Stammberger H, Jakse R, Beaufort F. Aspergillosis of the paranasal sinuses X-ray diagnosis, histopathology, and clinical aspects. *Ann Otol Rhinol Laryngol.* 1984;93(3 Pt 1):251-6.
 15. Ferguson BJ. Fungus balls of the paranasal sinuses. *Otolaryngol Clin North Am.* 2000;33(2):389-98.
 16. Zinreich SJ, Kennedy DW, Malat J, Curtin HD, Epstein JI, Huff LC, et al. Fungal sinusitis: Diagnosis with CT and MR imaging. *Radiology.* 1988;169(2):439-44.
 17. Bardana EJ, Jr. The clinical spectrum of aspergillosis-part 2: Classification and description of saprophytic, allergic, and invasive variants of human disease. *Crit Rev Clin Lab Sci.* 1981;13(2):85-159.
 18. Margie BG, Andrew. Nasal cavity, paranasal sinuses, nasopharynx infectious lesions: Fungal ball. 2016.
 19. Klossek JM, Peloquin L, Fourcroy PJ, Ferrie JC, Fontanel JP. Aspergillomas of the sphenoid sinus: A series of 10 cases treated by endoscopic sinus surgery. *Rhinology.* 1996;34(3):179-83.
 20. Ferreiro JA, Carlson BA, Cody DT 3rd. Paranasal sinus fungus balls. *Head Neck.* 1997;19(6):481-6.
 21. Moeller CW, Welch KC. Prevention and management of complications in sphenoidotomy. *Otolaryngol Clin North Am.* 2010;43(4):839-54.
 22. Wormald PJ. Surgery of the bulla ethmoidalis, middle turbinate, and posterior ethmoids and sphenoidotomy, including three-dimensional reconstruction of the posterior ethmoids. *Endoscopic sinus surgery: Anatomy, three-dimensional reconstruction, and surgical technique.* Thieme Medical Publishers, New York. 2008:101-14.
 23. Kainz J, Stammberger H. Danger areas of the posterior rhino basis: An endoscopic and anatomical-surgical study. *Acta Otolaryngol.* 1992;112(5):852-61.
 24. Elwany S, Elsaeid I, Thabet H. Endoscopic anatomy of the sphenoid sinus. *J Laryngol Otol.* 1999;113(2):122-6.